

# Mesenchymal Chondrosarcoma of the Sinonasal Tract: A Clinicopathological Study of 13 Cases With a Review of the Literature

P. Daniel Knott, MD; Francis H. Gannon, MD; Lester D. R. Thompson, MD

**Objectives/Hypothesis:** Mesenchymal chondrosarcoma of the sinonasal tract is a rare, malignant tumor of extraskeletal origin. Isolated cases have been reported in the English literature, with no large series evaluating the clinicopathological aspects of these tumors. **Study Design:** Retrospective review. **Methods:** Thirteen patients with sinonasal mesenchymal chondrosarcoma were retrieved from the Otorhinolaryngologic—Head and Neck Registry of the Armed Forces Institute of Pathology. **Results:** Nine women and 4 men (age range, 11 to 83 y; mean age, 38.8 y) presented with nasal obstruction (n = 8), epistaxis (n = 7), or mass effect (n = 4), or a combination of these. No patients reported prior head and neck irradiation. The maxillary sinus was the most common site of involvement (n = 9), followed by the ethmoid sinuses (n = 7) and the nasal cavity (n = 5). Tumors had an overall mean size of 5.1 cm. Microscopically, the tumors displayed a small, blue, round cell morphology appearance arranged in a hemangiopericytoma-like pattern with foci of cartilaginous matrix. All cases were managed by surgery with adjuvant radiation therapy (n = 4) and/or chemotherapy (n = 3). The overall mean survival was 12.1 years, although five of six patients who developed local recurrences died of disease (mean survival, 6.5 y). Six patients were alive and disease free (mean survival, 17.3 y), and two patients were lost to follow-up. **Conclusions:** Mesenchymal chondrosarcoma of the sinonasal tract is an aggressive tumor with a predilection for young women. The pattern of growth and scarcity of cartilaginous matrix result in frequent misdiagnosis. Recurrence

develops in approximately one-third of patients and seems to predict a poor prognosis. Aggressive, extensive surgery combined with adjuvant therapy appears to yield the best clinical outcome. **Key Words:** Mesenchymal chondrosarcoma, sinonasal tract, nasal cavity, prognosis, differential diagnosis.

*Laryngoscope*, 113:783–790, 2003

## INTRODUCTION

Mesenchymal chondrosarcoma (MC) is a rare, malignant cartilaginous tumor first described in 1959 by Lichtenstein and Bernstein.<sup>1</sup> Mesenchymal chondrosarcoma is a subtype of chondrosarcoma, accounting for up to 8% of all chondrosarcomas (irrespective of location).<sup>2–8</sup> It has been described as a particularly aggressive neoplasm in skeletal locations with a high tendency for late recurrence and delayed distant metastasis.<sup>2–6,9,10</sup> Mesenchymal chondrosarcoma of the sinonasal tract (MCSNT) is a rare tumor with only seven well-documented, histologically confirmed case reports in the English literature (MEDLINE, 1966–2002).<sup>11–17</sup> To the best of our knowledge, a comprehensive, clinicopathological evaluation of MCSNT has not been reported. Therefore, it is the intention of the current study to present the clinical features, histological findings, and follow-up information of 13 patients with MCSNT in comparison with those reported in the literature, in an effort to enhance the understanding of this neoplasm.

## MATERIALS AND METHODS

The records of 57 patients with head and neck tumors diagnosed as “mesenchymal chondrosarcoma” were identified in the files of the Otorhinolaryngologic—Head and Neck Registry of the Armed Forces Institute of Pathology (AFIP) from 1970 to 1995. However, 40 cases were excluded from further consideration because they involved the orbit, mandible, neck, or scalp. We included only cases primarily involving the nasal cavity and paranasal sinuses (sphenoid, maxillary, ethmoid, and frontal sinuses). Furthermore, an additional four cases were excluded because the small size of the biopsy specimen yielded only a single slide for analysis. Therefore, the remaining 13 patients make up the subject of this study, chosen from a review of 19,742 (0.07%) benign or malignant primary sinonasal tract tumors seen in consultation during this time period. The cases were obtained from civilian sources, including two foreign countries. Two patients included in

From the Department of Otolaryngology and Communicative Disorders (P.D.K.), Cleveland Clinic Foundation, Cleveland, Ohio; and the Departments of Orthopedic Pathology (F.H.G.) and Endocrine and Otorhinolaryngologic—Head and Neck Pathology (L.D.R.T.), Armed Forces Institute of Pathology, Washington, DC, U.S.A.

The opinion and assertions expressed herein are the private views of the authors and are not to be construed as official or as representing the views of the Department of Defense.

Editor's Note: This Manuscript was accepted for publication December 11, 2002.

Send Correspondence to Lester D. R. Thompson, MD, Department of Endocrine and Otorhinolaryngologic—Head and Neck Pathology, Building 54, Room G066-11, Armed Forces Institute of Pathology, 6825 16th Street Northwest, Washington, DC 20306-6000, U.S.A. E-mail: lester@thompsons2.com

TABLE I.  
Review of Sinonasal Tract Mesenchymal Chondrosarcoma Reported in the English Literature.

Patient Reported	Age (y)/Sex	Location (side)	Treatment	Patient Outcome (y)
1 <sup>11*</sup>	24/F	Middle turbinate (L)	Subtotal maxillectomy; radiation	A, NED (14.0)
2 <sup>12*</sup>	23/F	Maxillary sinus and orbital floor (R)	Radiation; wide exenteration	A, NED (2.0)
3 <sup>13</sup>	16/F	Ethmoid sinus (R)	En bloc resection	A, NED (0.7)
4 <sup>14</sup>	62/M	Maxillary sinus (R)	Chemotherapy	D, D (3.9)
5 <sup>15</sup>	1 d/M	Nasal cavity (R)	Chemotherapy; en bloc resection	A, NED (NR)
6 <sup>16</sup>	32/F	Maxillary sinus (L)	Maxillectomy	A, NED (9.0)
7 <sup>17</sup>	14/F	Maxillary antrum (R)	Preoperative chemotherapy; partial maxillectomy	A, NED (1.0)

\*These two patients are included in our series as patients 6 and 3, respectively.

Age in years; d = day; A, NED = alive with no evidence of disease; D, D = dead with disseminated disease; N/R = not reported.

the present review have been previously reported by other authors,<sup>11,12</sup> but additional clinical and follow-up information was obtained, so they are included in the current study.

Materials within the files of the AFIP were supplemented by a review of the patient demographics (gender, age, and ethnicity), signs and symptoms at clinical presentation (including duration), and predisposing factors (including prior irradiation). In addition, we reviewed surgical pathological and operative reports and obtained follow-up information from oncology data services by written questionnaires or direct communication with the treating physician or the patient. Follow-up data included exact tumor location, tumor size, treatment modalities, and current patient and disease status. The present clinical investigation was conducted in accordance and compliance with all statutes, directives, and guidelines of the Code of Federal Regulations, Title 45, Part 46, and the Department of Defense Directive 3216.2 relating to human subjects in research. Hematoxylin and eosin (H&E)-stained slides from all patients were reviewed for morphological assessment of MC, with histological confirmation of the original AFIP diagnosis by a consensus agreement of all the authors. Five- and 10-year disease-free survivals were calculated based on the presence or absence of disease at each interval. Because of the limited number of cases, no statistical model was deemed satisfactory to yield meaningful results.

Our review of primary MCSNT in the English literature was based on a MEDLINE search from 1966 to 2002, with a few earlier reports included because of the rarity of the neoplasm (Table I). Reports describing MC in general were analyzed for comparison, although many cases have been reported a number of times from the same institution.<sup>4,6,18,19</sup>

## RESULTS

### *Sociodemographic Characteristics and Clinical Findings*

The patients included 4 men and 9 women ranging in age from 11 to 83 years (mean age, 38.8 y; median age, 29 y [Table II]). There was no difference in the mean or median age at presentation between the genders. All of the patients were Caucasian. The patients complained of nasal obstruction (n = 8 [62%]), epistaxis (n = 7 [54%]), and/or mass effect (n = 4 [31%]). Other symptoms included pain, nasal discharge, headache, and facial asymmetry. Symptoms were experienced during a period ranging from 2 weeks to 2 years (mean period, 7.8 mo). No patient in the present clinical series had a history of prior radiation exposure, either thera-

peutic or environmental. Furthermore, no patient had a syndrome-associated chondrosarcoma.

### *Radiographic Studies*

Radiographic studies were performed for the majority of patients in the present review, although the actual films may have been returned to the contributing hospital before the current study, allowing for only a review of the radiology report or radiological facsimile copy. Most patients (especially in the cases before 1980) had plain x-ray films, whereas advanced imaging techniques, such as computerized tomography (CT) scans or magnetic resonance imaging (MRI) studies, or both, were added to the workup in most patients after 1980. In general, a mass lesion of variable density (compared with adjacent muscle) was identified replacing the sinuses and/or nasal cavity, demonstrating fine, punctate stippled to coarse ("pop-

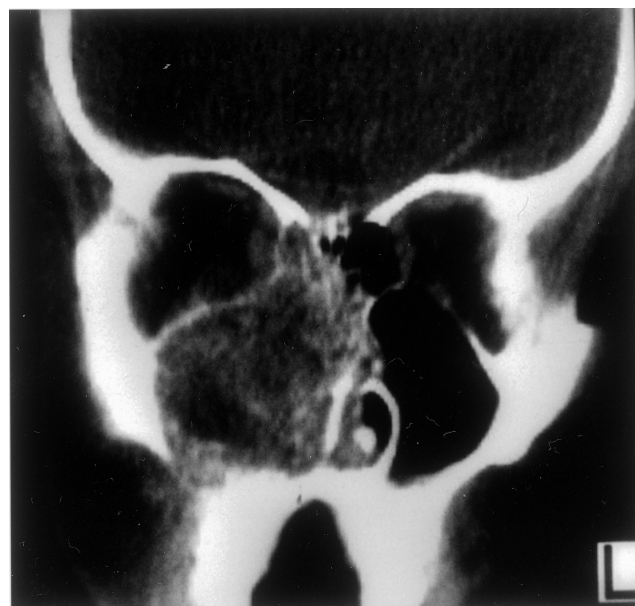

Fig. 1. A coronal computed tomography scan shows complete opacification of the maxillary sinus by the mesenchymal chondrosarcoma with bony destruction. Tumor calcifications are easily demonstrated.



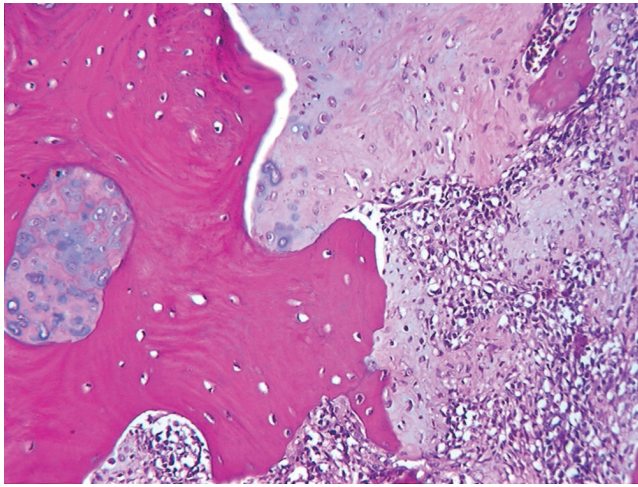


Fig. 2. Normal Haversian bone is invaded by chondrosarcoma that imperceptibly blends with areas of undifferentiated mesenchymal cells (lower right).

corn”) calcification within the tumor (Fig. 1). Nearly all of the tumors were noted to have some form of calcification. Tumors were ill-defined with an expansile radiolucent mass invading into and destroying the bone of the nasal cavity and sinuses. Extension into the surrounding sinuses, orbit, and skull was frequently demonstrated. When a mucosal surface was obvious, it was intact.

### Pathological Features

**Macroscopic findings.** The most frequently involved site was the maxillary sinus (n = 9), followed by the ethmoid sinuses (n = 7) and the nasal cavity (n = 5). The tumors invaded the surrounding bone to involve the orbit (n = 2), cribriform plate (n = 2), dura and middle fossa (n = 2), or palate (n = 1). The tumors were centered on the left (n = 5) or right (n = 4) side; the laterality was unknown in four patients. The tumors were large and ranged in size from 3.2 to 9.0 cm (mean value, 5.1 cm; median

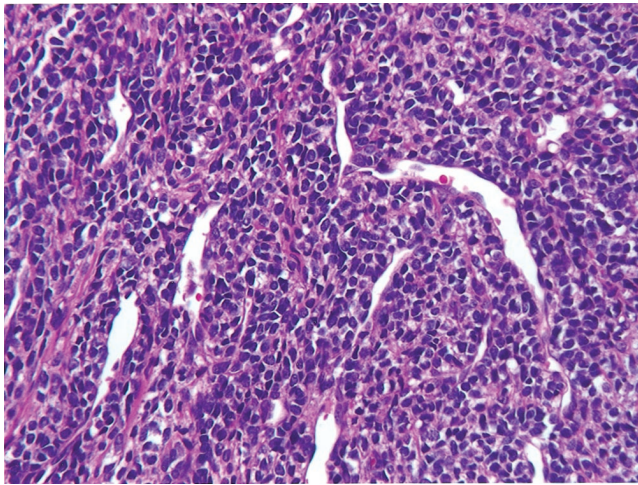


Fig. 3. Small cells with scant cytoplasm arranged in a hemangiopericytoma-like pattern around patulous vascular channels.

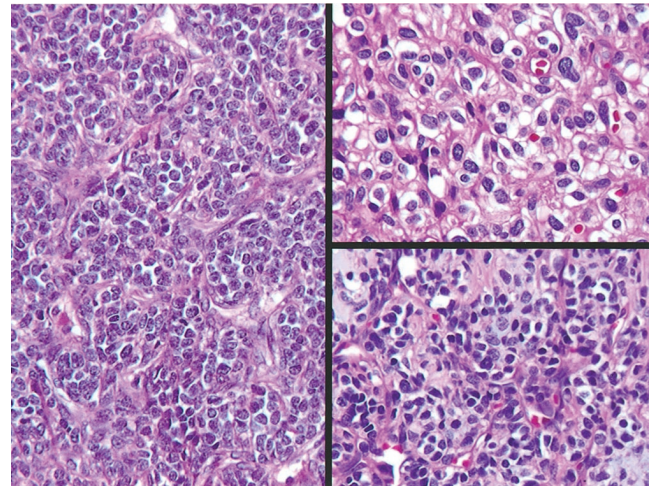


Fig. 4. The more typical mesenchymal chondrosarcoma with the cells arranged in a packaged or nested pattern (left), with an accentuation of the intercellular borders and an “eosinophilic” tinge in the stroma (upper right) and a hint of basophilic matrix material (lower right).

value, 4.5 cm). The majority of tumors were received as specimens following total surgical excision and were described as irregular blue-gray to reddish-tan fragments of mucosa covered tissue, with focal areas of hemorrhage and clot.

**Microscopic findings.** Bone invasion by neoplastic chondrocytes or undifferentiated mesenchymal cells was identified in all tumors with sufficiently large biopsy specimens (Fig. 2). The neoplastic cells were variously arranged in sheet-like patterns and organized around open vascular spaces in a pattern reminiscent of sinonasal-type hemangiopericytoma (Fig. 3). Other patterns included a nested (“alveolar”) architecture and solid pattern (Fig. 4). All of the tumors revealed more than one pattern with the

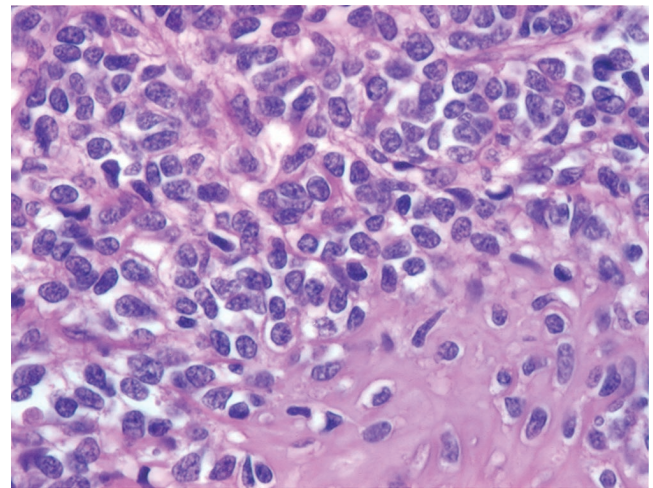


Fig. 5. The chondroid matrix shows the lacunar spaces filled with the same nuclei as identified in the mesenchymal component. Vague lacunar spaces are seen around the undifferentiated mesenchymal cells, which display coarse nuclear chromatin in irregularly shaped nuclei.



transition between these patterns being abrupt and discrete in some regions and gradual in others. All tumors, to a variable degree, demonstrated the typical bimorphic pattern of MC, with richly cellular, undifferentiated, small mesenchymal cells intermixed with islands of relatively well-differentiated and comparatively benign-appearing cartilage (Fig. 5). The chondroid element varied from virtually indistinguishable foci to large masses of well-defined cartilage. In a few cases, many sections were examined before the small foci of cartilage were revealed. The cartilage was composed of a homogenous matrix with extensions into the surrounding mesenchymal-type cells. Lacunae were present in the matrix and contained cells with regular, small, hyperchromatic nuclei, occasionally similar to the nuclei of the mesenchymal component, although usually comparable to other types of chondrosarcoma. Dysmorphic calcification was identified, but malignant osteoblasts or bone matrix was not seen. The mesenchymal cells were comparatively small and round to oval, with scant cytoplasm separating cells with prominent intercellular borders. In other areas the tumor cells were spindle-shaped, arranged in a storiform pattern (Fig. 6). The nuclei were hyperchromatic, with condensed chromatin seen at the periphery. Areas of myxoid degeneration (Fig. 6), hemorrhage, and necrosis were frequently identified, although these areas were not the dominant pattern. Osteoclast-like multinucleated giant cells were identified in three cases (Fig. 7), simulating a giant cell tumor. Mitotic figures were identified in all cases, although not increased in number (<2 per 10 high-power fields). Atypical forms were also noted.

Most of the cases were not classified correctly at initial consultation. Cases were diagnosed as hemangiopericytoma (n = 3), either benign or malignant, followed by embryonal rhabdomyosarcoma, fibrosarcoma, carcinoma ex-pleomorphic adenoma, fibrous histiocytoma, and lymphoma. Only five cases (38%) were correctly classified by the contributors.

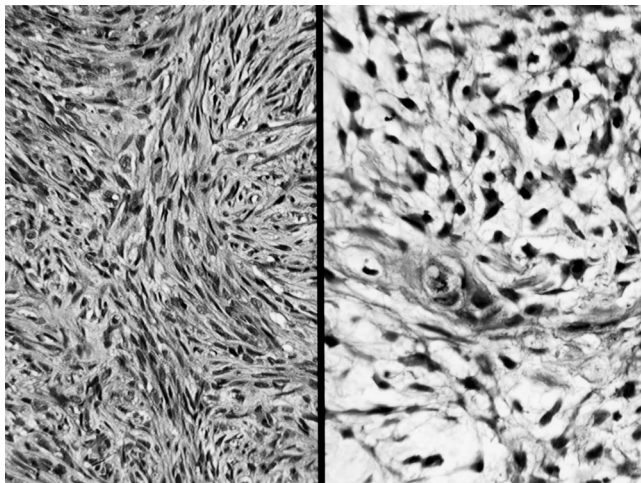


Fig. 6. A spindle cell component arranged in a storiform pattern with mitotic figure (left) was noted. A myxoid degeneration was not uncommon, making the cartilaginous nature of the neoplasm (center of right side) more difficult to recognize.

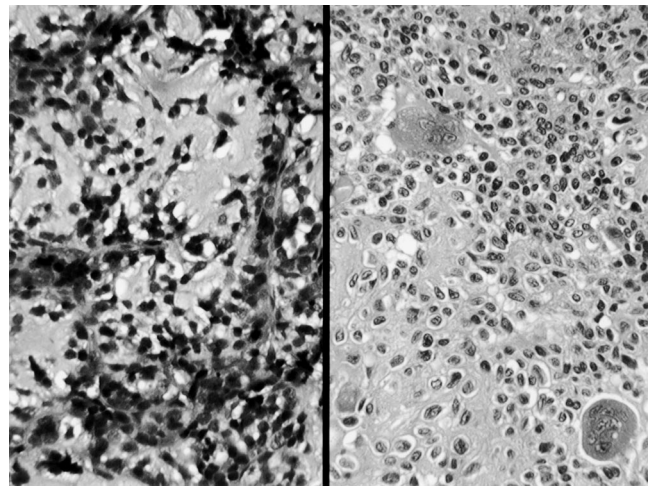


Fig. 7. Areas reminiscent of a pleomorphic adenoma (left). Several multinucleated giant cells adjacent to cartilaginous matrix material (right).

### Treatment and Follow-up

All patients were treated surgically with curettage (n = 1) or wide resection (n = 12). Wide resection included such procedures as lateral rhinotomy, maxillectomy, sphenoidectomy, and orbital exenteration, with debulking of intracranial and middle cranial fossa tumor. Of the 11 patients in whom follow-up was available (two foreign patients were lost to follow-up), four patients had radiation therapy, whereas three patients had chemotherapy (Table II). Only one patient (currently alive; follow-up, 26.6 y) had triple combination therapy. Specific patients deserve greater clarification. Preoperative radiation therapy was administered to patient 3 because her tumor was initially considered unresectable. Limited tumor regression was achieved, and she subsequently underwent maxillectomy and orbital exenteration. Despite developing panhypopituitarism and dacryocystitis as a postoperative complication, she is currently alive and disease free (follow-up, 22 y). Patient 6 developed an axillary lymph node metastasis 14 years after nasal resection and postoperative irradiation. Despite axillary lymphadenectomy, she developed additional metastases over the ensuing years and eventually died of disease 23.8 years after her primary presentation. Patient 7 experienced two local recurrences 4 and 5 years, respectively, after initial treatment. She was treated with orbital exenteration in conjunction with chemotherapy and radiation therapy. She is currently alive and disease free (follow-up, 26.6 y). Patient 8 developed extensive local recurrence and was treated with wide local resection of the skull base including dura, orbit, and nasal cavity. The patient died of disease (survival, 1 y). Patient 10 developed local recurrence in her maxillary sinus, buccal region, and anterior skull base, which was treated with chemotherapy (Cytosan, CCNU, Methotrexate). She died of her disease 1.8 years after presentation.

The overall mean survival for all patients was 12.1 years (median survival, 11.3 y). Of 6 patients who developed local recurrence 5 patients subsequently died of dis-

TABLE II.  
Sinonasal Tract Mesenchymal Chondrosarcomas.

Patient No.	Age (y)/Sex	Location (side); Size (cm)	Symptoms (duration in mo)	Treatment	Patient Outcome (y)
1	11/F	Nasal cavity; N/R	Epistaxis, nasal obstruction (6)	Excision	LTF
2	15/F	Maxillary and ethmoid sinuses with erosion of cribriform plate (R); 5.0	Epistaxis, nasal obstruction (5)	Maxillectomy and skull base exenteration	A, NED (11.3)
3	23/F	Maxillary sinus and orbital floor (R); 9.0	Swelling and pain (4)	Preoperative radiation; wide excision with orbital exenteration	A, NED (22)
4	24/M	Nasal cavity (R); 3.4	Nasal obstruction, mass (8)	Preoperative chemotherapy; partial maxillectomy	A, NED (8.0)
5	24/M	Maxillary sinus (L); 4.2	Epistaxis (0.5)	Wide local excision	D, D (2.7)
6	24/F	Middle turbinate (L); 4.5	Epistaxis, nasal obstruction (8)	Subtotal maxillectomy; radiation (4300 rads)	D, D (23.8)
7	29/F	Maxillary, sphenoid and ethmoid sinuses (L); 4.1	Epistaxis and headache (1)	Partial maxillectomy, sphenoidectomy; chemotherapy; radiation	A, NED (26.6)
8	30/M	Maxillary, ethmoid and sphenoid sinus (L); 5.0	Facial swelling (24)	Hemimaxillectomy	D, D (1.0)
9	36/F	Maxillary sinus (R); 3.8	Nasal obstruction, pain (2)	Excision	A, NED (23.2)
10	60/F	Maxillary and ethmoid sinuses (R); 3.2	Epistaxis, nasal obstruction (3)	Wide local excision; chemotherapy	D, D (1.8)
11	69/F	Ethmoid sinus (L); 8.0	Epistaxis, nasal obstruction (24)	Maxillectomy, orbital exenteration, and craniotomy; radiation	A, NED (12.7)
12	75/M	Nasal cavity and ethmoid sinus; N/R	N/R	Curettage	LTF
13	83/F	Nasal cavity, maxillary and ethmoid sinuses (L); 5.5	Nasal obstruction (N/R)	Excision	D, D (0.4)

N/R = not reported; D, D = dead with disseminated disease; A, NED = alive, no evidence of disease; LTF = lost to follow-up.

ease (mean survival, 6.5 y; median survival, 1.8 years), even though one patient developed two distant metastases and died 23.8 years after initial treatment. The remaining six patients are alive and disease free, with a mean survival of 17.3 years (median survival, 17.3 y). Two patients were lost to follow-up (Table II). These results yielded a disease-free 5-year survival rate of 64% and a disease-free 10-year survival rate of 55%.

## DISCUSSION

Chondrosarcomas of the head and neck are rare, accounting for approximately 0.1% of all head and neck cancers.<sup>20</sup> Chondrosarcoma may arise from any bone or soft tissue site, although fewer than 1% of these tumors are of extraskeletal origin.<sup>5</sup> The histological diagnosis of chondrosarcoma was based on criteria for malignant cartilaginous tumors elsewhere in the body, first set forth by Lichtenstein and Jaffe,<sup>21</sup> with tumor grading added at a later time.<sup>22</sup> Chondrosarcomas are recognized by their increased cellularity, nuclear atypia including binucleation and multinucleation, and propensity to invade and destroy surrounding structures. Chondrosarcomas are divided into a number of subtypes, including myxoid, dedifferentiated, clear cell, and mesenchymal types. Mesenchymal chondrosarcomas makes up approximately 2% of all chondrosarcomas.<sup>2,3,20</sup> In the present series and in other series, MCSNT makes up a small percentage (0.07%) of all benign and malignant primary sinonasal tract neoplasms, confirming the rare nature of this curious neoplasm.<sup>2</sup>

Mesenchymal chondrosarcoma of the sinonasal tract affects women twice as commonly as men and, in general, presents in the third and fourth decades of life (mean age at presentation, 34.8 y) (Table III). The age at initial presentation is indistinguishable from MC in other body

TABLE III.  
Composite Results of the Present Series and the Reported Literature of Sinonasal Tract Mesenchymal Chondrosarcoma.

Feature	No.
Total number of patients	18
Females	12
Males	6
Age at presentation	
Mean age (y)	34.8
Median age (y)	26.5
Mean duration of symptoms (mo)	9.4
Mean tumor size (cm)	5.3
Patient outcome	
Overall survival, mean (y)	9.9
Patients without evidence of disease (mean follow-up)	10 (12.7)
Patients who developed recurrences (mean follow-up)	6 (6.1)
Patients who developed metastases (mean follow-up)	4 (7.7)
Patients who died with disease (mean follow-up)	6 (5.6)

sites<sup>2-10,23-25</sup> but is in sharp contrast to chondrosarcoma as a whole, which tends to develop in the fifth to seventh decades of life.<sup>5</sup> Furthermore, MC in other anatomical sites does not exhibit such a remarkable female-to-male ratio; instead, the ratio is more one to one.<sup>5,6,8,26</sup> Among such a young cohort, a low index of suspicion for malignancy is expected, especially when the symptoms of MC-SNT are nonspecific. The most frequent complaints were epistaxis and nasal obstruction, hardly compelling symptoms.<sup>11-17</sup> These factors may explain the long duration of symptoms (mean duration, 9.4 mo) before treatment is sought (Table III).

Imaging is important both in diagnosis and in treatment planning. Although not pathognomonic, the findings of matrix calcification, enhancement, neovascularity, lobulation, and osteolysis and bone destruction allude to a sarcomatous process.<sup>2,5-7,23,24,26</sup> Because of the inherent technical difficulties in completely removing tumors from the sinonasal tract, three-dimensional CT scanning may also improve planning of composite resections,<sup>27</sup> which were performed in five of the patients in the present series and those reported in the literature (Tables I and II).<sup>12,13,15</sup>

The head and neck region is a frequent location for this tumor, although the majority of mesenchymal chondrosarcomas occur in the axial skeleton.<sup>3,6,23</sup> In the head and neck region, the jaws and skull are the most common sites of origin,<sup>2,5,6,8,18,24</sup> with extraskeletal involvement of the sinonasal tract rarely reported. Within the sinonasal tract, the maxillary sinus (n = 11) is most commonly affected, followed by the ethmoid sinuses (n = 8) and the nasal cavity (n = 6) (Table III).<sup>11-17</sup>

Mesenchymal chondrosarcomas of other anatomical sites are typically large, bulky tumors with an average size of greater than 10 cm, quite different from those of the sinonasal tract.<sup>5,6,23</sup> We think that the anatomical confines of the sinonasal tract compel the patient to seek medical attention while the tumor is still relatively small, in contrast to skeletal lesions, although quite sizable (mean, 5.3 cm) in comparison with other sinonasal tract neoplasms.<sup>11-17</sup>

A confounding factor in the diagnosis of MC is the size of the biopsy specimen. It is not uncommon for an initial biopsy specimen or single section of embedded material to contain only one of the two elements. This accounts for the high percentage of cases that are misclassified. Although radiographic studies invariably demonstrate calcification, multiple sections of the tumor mass are usually needed to make an accurate diagnosis. The key to the diagnosis relies on a careful and thorough search for the scanty areas of chondroid differentiation.

The combination of innocuous-appearing chondroid foci and highly undifferentiated mesenchymal cells is inimitable for MC. The transition zones from small, undifferentiated cells into areas of spindle cell formation and then blending with cartilaginous islands is pathognomonic of the neoplasm.<sup>1,6</sup> The cartilage is relatively bland in comparison to the mesenchymal component, but all mesenchymal chondrosarcomas are considered high-grade neoplasms by definition.<sup>6,22</sup> When osseous tissue can be seen at the periphery of the tumor, it represents a meta-

plastic process rather than a true malignant osteoid component.<sup>3,4</sup>

The clustering of the tumor cells around patulous vessels is reminiscent of hemangiopericytoma, but the size and shape of the cells are not typical of a hemangiopericytoma. The hemangiopericytoma-like growth pattern was seen to some degree in each tumor, so we did not choose to separate tumors into the "hemangiopericytoma-like" and "small cell" types, especially since there does not appear to be any prognostic significance to such a separation.<sup>5,26</sup> Sinonasal-type hemangiopericytoma does not contain areas of chondroid differentiation.

The poorly differentiated mesenchymal cells occasionally had more "prominent" cellular borders to suggest "chondroid" cellular traits. However, in general, the cells seem to be in direct contact with one another without intervening stroma or matrix material. It has been suggested that MC arises from primitive or embryonal-type elements and follows the cellular events similar to fetal chondrogenesis.<sup>3,5,28</sup> Therefore, perhaps MC will show variable degrees of cellular differentiation within the lesion as it develops, demonstrating primitive cells juxtaposed with minute fields of cartilage or areas of ossification.<sup>3</sup>

Although the pathological diagnosis is distinct and unique, it remains a significant challenge, as confirmed in the present clinical series. Only five tumors (38%) were accurately diagnosed on initial analysis by the contributing pathologists. Other small cell neoplasms such as lymphoma, Ewing sarcoma, embryonal rhabdomyosarcoma, synovial sarcoma, small cell osteosarcoma, and undifferentiated carcinoma may initially be confused with MC.<sup>2,6,18,23</sup> However, the identification of chondroid matrix within the background mesenchyme clarifies the diagnosis. Giant cells are noted in a number of tumors, but it is the overall pattern and presence of cartilage that yield an accurate diagnosis. Although no immunophenotypic analysis was performed in the present clinical analysis, it is well known that MC is a primitive neoplasm which demonstrates polyphenotypic differentiation (S-100 protein, desmin, myoD1) that overlaps other small cell malignancies (Ewing sarcoma, small cell osteosarcoma, primitive neuroectodermal tumors).<sup>10,24</sup> Therefore, given the unusual nature of the neoplasm, referral to a center with expertise in the diagnosis and management of the lesion is suggested.

Surgery is the primary treatment modality, although the specific procedure varies greatly in accordance with the specific location and extent of disease.<sup>2,4,6,9,23,29</sup> Because of the complex anatomy of the sinonasal tract and the proximity of vital structures, it is difficult to achieve true oncological resection while maintaining cosmesis and preserving function. Specific details regarding management are incomplete, because of the nature of our referral service. However, surgery, often of a radical nature, was used in nearly all patients, with neoadjuvant or postoperative irradiation (n = 4) or combination radiation therapy and chemotherapy. Similar procedures were carried out for the patients reported in the literature.<sup>11-17</sup> The overall role of multimodality treatment remains uncertain.<sup>4,6,9,10,23</sup> Neoadjuvant radiation therapy was used in



one patient in the present series, resulting in a decreased tumor size, a finding similar to a few case reports in the literature.<sup>7</sup> When concomitant chemotherapy has been used for MC, there is, in general, no decrease in overall tumor size.<sup>14,27,30</sup> Standardization of treatment of chondrosarcoma of the head and neck has been difficult because of recognized differences of biological behavior at varying anatomical sites.<sup>12</sup> For example, intraspinal dural-based MC enjoys a more favorable prognosis suggested by earlier diagnosis and treatment precipitated by acute cord compression by small tumors still early in the growth cycle.<sup>10</sup> Similarly, MCSNT may present relatively earlier in the disease course than MC of other anatomical sites and therefore benefits from earlier surgical treatment. Given the rarity of MCSNT, it may be of value to use radiotherapy and/or chemotherapy to achieve the best possible patient outcome.<sup>6,9</sup>

The clinical course is characterized by profound variability, irrespective of anatomical location. Patients may experience symptoms for weeks to years, have a propensity to develop recurrences from months to years after initial presentation, and die of their disease after a quiescent period of up to 25 years after initial presentation.<sup>4,6,9,10</sup> Among our cohort, disease-free 5-year and 10-year survival rates were 64% and 55%, respectively, with an overall mean survival of 12.1 years. This suggests that if patients survive the first five years without the development of a recurrence, they are unlikely to die of their disease. This represents an difference vis-à-vis the MC patients as a whole reported in the literature, where there was a raw 5-year survival of 35% to 60% and a raw 10-year survival of 20% to 40%.<sup>3-5,9,23</sup> Jaw lesions have also been reported to have a better prognosis: 5-year and 10-year survival rates of 82% and 56%, respectively.<sup>8</sup> Furthermore, in the sinonasal tract, 63% of patients survive without evidence of disease, suggesting earlier clinical detection of lesions in the head and neck in general.<sup>8,10-17</sup>

Mesenchymal chondrosarcoma may pursue a rapid clinical course and can metastasize in a high percentage of cases.<sup>5,9,9,23</sup> When a recurrence occurs, as it did in 38% of patients in the present series, it is a harbinger of a worse clinical outcome because nearly all of these patients ultimately died of their disease with metastatic tumors. When metastases occur, it is primarily through a hematogenous route, with the lungs being the most common secondary site of involvement.<sup>6,15,23</sup> Adequate radical local control is necessary if metastatic disease is to be prevented.

## CONCLUSION

Mesenchymal chondrosarcoma of the sinonasal tract is a highly malignant small cell tumor, which often presents with symptoms of nasal obstruction and epistaxis in young women. It is commonly misdiagnosed on pathological analysis, because of the dearth of cartilaginous matrix. Mesenchymal chondrosarcoma of the sinonasal tract appears less aggressive than MC of other anatomical sites, perhaps because of an earlier clinical presentation. Optimal treatment remains ablative surgical therapy, with a possible benefit from irradiation and chemotherapy. Diligent, close clinical surveillance is required because the clinical course may be protracted by delayed recurrence or

metastasis. With aggressive initial therapy, more than 60% long-term patient survival is possible (mean survival, 9.9 y).

## Acknowledgments

The authors thank Robert Weisman for inspiring an investigation into mesenchymal chondrosarcoma of the head and neck.

## BIBLIOGRAPHY

- Lichtenstein L, Bernstein D. Unusual benign and malignant chondroid tumors of bone: a survey of some mesenchymal cartilage tumors and malignant chondroblastic tumors, including a few multicentric ones, as well as many atypical benign chondroblastomas and chondromyxoid fibromas. *Cancer* 1959;12:1142-1157.
- Bertoni F, Picci P, Bacchini P, et al. Mesenchymal chondrosarcoma of bone and soft tissues. *Cancer* 1983;52:533-541.
- Dabska M, Huvos AG. Mesenchymal chondrosarcoma in the young. *Virchows Arch A Pathol Anat Histopathol* 1983;399:89-104.
- Dahlin DC, Henderson ED. Mesenchymal chondrosarcoma: further observations on a new entity. *Cancer* 1962;15:410-417.
- Huvos AG, Rosen G, Dabska M, Marcove RC. Mesenchymal chondrosarcoma: a clinicopathologic analysis of 35 patients with emphasis on treatment. *Cancer* 1983;51:1230-1237.
- Nakashima Y, Unni KK, Shives TC, Swee RG, Dahlin DC. Mesenchymal chondrosarcoma of bone and soft tissue: a review of 111 cases. *Cancer* 1986;57:2444-2453.
- Shapeero LG, Vanel D, Couanet D, Contesso G, Ackerman LV. Extraskeletal mesenchymal chondrosarcoma. *Radiology* 1993;186:819-826.
- Vencio EF, Reeve CM, Unni KK, Nascimento AG. Mesenchymal chondrosarcoma of the jaw bones: clinicopathologic study of 19 cases. *Cancer* 1998;82:2350-2355.
- Harwood AR, Krajchich JI, Fornasier VL. Mesenchymal chondrosarcoma: a report of 17 cases. *Clin Orthop* 1981:144-148.
- Rushing EJ, Armonda RA, Ansari Q, Mena H. Mesenchymal chondrosarcoma: a clinicopathologic and flow cytometric study of 13 cases presenting in the central nervous system. *Cancer* 1996;77:1884-1891.
- Bloch DM, Bragoli AJ, Collins DN, Batsakis JG. Mesenchymal chondrosarcomas of the head and neck. *J Laryngol Otol* 1979;93:405-412.
- Finn DG, Goepfert H, Batsakis JG. Chondrosarcoma of the head and neck. *Laryngoscope* 1984;94:1539-1544.
- Takimoto T, Kato H, Yamashita T, Yamashita J, Umeda R. Mesenchymal chondrosarcoma of the ethmoid sinus. *ORL J Otorhinolaryngol Relat Spec* 1989;51:369-374.
- Ito T, Hiratsuka H, Kohama G. Mesenchymal chondrosarcoma of the maxilla: report of a case. *Int J Oral Maxillofac Surg* 1991;20:44-45.
- Roland NJ, Khine MM, Clarke R, Van Velzen D. A rare congenital intranasal polyp: mesenchymal chondrosarcoma of the nasal region. *J Laryngol Otol* 1992;106:1081-1083.
- Mateos M, Forteza G, Gay-Escoda C. Mesenchymal chondrosarcoma of the maxilla: a case report. *Int J Oral Maxillofac Surg* 1997;26:210-211.
- Chidambaram A, Sanville P. Mesenchymal chondrosarcoma of the maxilla. *J Laryngol Otol* 2000;114:536-539.
- Salvador AH, Beabout JW, Dahlin DC. Mesenchymal chondrosarcoma: observations on 30 new cases. *Cancer* 1971;28:605-615.
- Scheithauer BW, Rubinstein LJ. Meningeal mesenchymal chondrosarcoma: report of 8 cases with review of the literature. *Cancer* 1978;42:2744-2752.
- Koch BB, Karnell LH, Hoffman HT, et al. National cancer database report on chondrosarcoma of the head and neck. *Head Neck* 2000;22:408-425.

21. Lichtenstein L, Jaffe H. Chondrosarcoma of bone. *Am J Pathol* 1943;19:553–574.
22. Evans HL, Ayala AG, Romsdahl MM. Prognostic factors in chondrosarcoma of bone: a clinicopathologic analysis with emphasis on histologic grading. *Cancer* 1977;40:818–831.
23. Guccion JG, Font RL, Enzinger FM, Zimmerman LE. Extraskeletal mesenchymal chondrosarcoma. *Arch Pathol* 1973;95:336–340.
24. Hoang MP, Suarez PA, Donner LR, et al. Mesenchymal chondrosarcoma: a small cell neoplasm with polyphenotypic differentiation. *Int J Surg Pathol* 2000;8:291–301.
25. Takahashi K, Sato K, Kanazawa H, Wang XL, Kimura T. Mesenchymal chondrosarcoma of the jaw: report of a case and review of 41 cases in the literature. *Head Neck* 1993;15:459–464.
26. Huvos AG, Marcove RC. Chondrosarcoma in the young: a clinicopathologic analysis of 79 patients younger than 21 years of age. *Am J Surg Pathol* 1987;11:930–942.
27. Ariyoshi Y, Shimahara M. Mesenchymal chondrosarcoma of the maxilla: report of a case. *J Oral Maxillofac Surg* 1999; 57:733–737.
28. Fu YS, Kay S. A comparative ultrastructural study of mesenchymal chondrosarcoma and myxoid chondrosarcoma. *Cancer* 1974;33:1531–1542.
29. Christensen RE. Mesenchymal chondrosarcoma of the jaws. *Oral Surg Oral Med Oral Pathol* 1982;54:197–206.
30. Bottrill ID, Wood S, Barrett-Lee P, Howard DJ. Mesenchymal chondrosarcoma of the maxilla. *J Laryngol Otol* 1994; 108:785–787.